

## Hair transplantation for the treatment of post-irradiation alopecia

Jerzy Kolasiński, Małgorzata Kolenda, Janusz Skowronek

*Introduction.* Treatment of head and neck tumours and of leukaemia often necessitates radiotherapy. However, permanent alopecia in the scalp exposed to irradiation is a common problem.

*Material and methods.* One of the effective methods of treatment of post-irradiation alopecia is hair transplantation. Over a period of 18 years 42 patients were treated at the Hair Clinic Poznań for post-irradiation alopecia. Due to the presence of numerous lesions in the donor and recipient scalp areas many modifications were introduced into alopecia correction.

*Results.* The treatment assured good cosmetic effects, free of the risk of complications.

*Discussion.* Scalps from occipital areas do not go bald when transferred to scalp areas affected by balding. On the contrary - they retain original properties, thus resulting in hair re-growth. Hair follicle transplantation is usually applied for the correction of androgenic alopecia in men and women although it may also be applied in post-trauma and post-irradiation alopecia treatment. Hair regrowth in radiotherapy patients occurs later than in androgenic alopecia patients. This phenomenon is caused by blood supply deficits in the recipient area.

*Summary.* Autogenic hair follicle transplantation is a treatment of choice in the correction of post-irradiation alopecia, while the good cosmetic effects considerably improve the patients' quality of life.

### Przeszczep włosów w leczeniu łysienia po napromienianiu

*Wstęp.* Leczenie chorób nowotworowych w obrębie głowy i szyi, a także leczenie białaczek wymaga często radioterapii. Konsekwencją takiego postępowania jest wielokrotnie trwale łysienie obszarów skóry owłosionej głowy, poddanej ekspozycji na promieniowanie.

*Materiał i metody.* Jednym ze skutecznych sposobów leczenia łysienia poradiacyjnego jest przeszczep włosów. W okresie 18 lat leczono w Hair Clinic Poznań 42 pacjentów z powodu łysienia popromiennego. Ze względu na zmiany w obrębie skóry okolicy biorczej i dawczej zastosowano szereg modyfikacji korekcji łysienia.

*Wyniki.* Zastosowane leczenie pozwoliło na uzyskanie satysfakcjonujących efektów kosmetycznych bez ryzyka wystąpienia powikłań.

*Dyskusja.* Włosy pobrane z okolicy potylicznej głowy, nie podlegają łysieniu, a przeniesione w okolice łysiejące zachowują swoje właściwości i pozwalają uzyskać odrost włosów. Przeszczep włosów jest zwykle stosowany w korekcjach łysienia androgenowego u mężczyzn i kobiet, jak również w leczeniu łysienia po urazach i radioterapii. Odrost włosów u pacjentów po radioterapii następuje później niż u pacjentów z łysieniem androgenowym. Jest to spowodowane gorszym ukrwieniem okolicy biorczej.

*Podsumowanie.* Autogeny przeszczep mieszków włosowych jest leczeniem z wyboru w korekcji łysienia popromiennego, a uzyskanie dobrego efektu kosmetycznego znacznie poprawia komfort życia pacjentów.

**Key words:** hair transplantation, post-irradiation alopecia, post-burn alopecia, radiotherapy

**Słowa kluczowe:** przeszczep włosów, łysienie po napromienianiu, łysienie po oparzeniu skóry głowy, radioterapia

### Introduction

Integrated treatment of neoplasms involves surgery, radiotherapy and chemotherapy [1]. Unfortunately permanent alopecia in the scalp areas exposed to irradiation may be a common result of radiotherapy after the

treatment of leukaemias and central nervous system tumours [1-6].

In the early stages of irradiation large areas of the scalp undergo balding while after the therapy a partial regrowth of hair is observed. There are however areas of the head which are permanently devoid of hair. This constitutes a serious cosmetic defect, which may negatively influence the patient's wellbeing [3, 5, 7-12].

One of the effective methods of post-irradiation alopecia is autogenic hair follicle transplantation.

## Material and methods

Between December 1984 and January 2002 forty-two patients underwent treatment for post-irradiation alopecia at the Hair Clinic Poznań. The group consisted of 33 women (78.5%) and 9 men (21.5%); mean age 26.5 years; range: 15 – 60 yrs.

A majority of the patients had been subjected to irradiation in childhood and adolescence. Because the majority of our patients could not present radiotherapeutic documentation we have decided to omit its analysis in the paper. The indications for radiotherapy are presented in Table I.

**Table I. Causes for undergoing radiotherapy in the studied group**

Cause for radiotherapy	Number of patients	
Acute lymphoblastic leukaemia	18	42.8%
Brain tumours		
<i>astrocytoma</i>	6	14.4%
<i>meningioma</i>	9	21.4%
<i>ependymocytoma</i>	3	7.1%
Phlegmon of the scalp	6	14.4%

Patients reported for reconstructive treatment 1 to 50 years after radiotherapy, (an average of 12 years). All were treated by autogenic hair follicle transplantation. One patient underwent 1 to 4 surgical sessions an average of 2.2 per patient. Each procedure was performed under local anaesthesia (1% lignocaine with adrenaline). A scalp section was taken from areas with good hair density and constant hair growth, free of alopecia threat. The recipient area was sutured with continuous suture (Prolen 3-0). Then an adequate number of grafts was prepared by cutting the collected scalp fragment into micro- (1-2 hairs) and mini-grafts (3-4 hairs). Between 500 and 1500 grafts were performed in one session. The number of grafts depended on the size of the bald site and on hair density in the donor area. The prepared grafts were placed in 0.9% solution of saline at room temperature.

The grafts were placed in the scalp of the donor area by means of our own technique – *four hands stick and place*. In this technique grafts are successively placed in micro-incisions – immediately after the incisions were made with a SM-65 scalpel blade. The placement angle corresponds with the growth direction of residual hair in this area. Spaces of 1.5 to 2 mm are left between individual grafts.

After the procedure the surgery area was sprayed with Neomycin in aerosol and covered with vaseline dressing. The patient was given an oral antibiotic before the procedure – usually Doxycyclinum – and continued it up to day three after the procedure. On the following post-operative day the dressing was removed, the scalp was left without dressing and the patient was discharged.

Follow-up examination took place on day 7 to 10 postoperatively.

## Results

After 4-5 months very good hair regrowth was observed in all patients. On comparison with a group of androgenic alopecia patients, lower hair density and its smaller thickness were observed in post-irradiation patients. No inflammatory complications were noted.

A good or a very good cosmetic effect was achieved, which significantly improved our patients' psychological condition.

## Discussion

Radiotherapy results in post-irradiation reaction leading to scalp alopecia [7, 13-17]. Initially balding involves a large irradiated area. After a few months hair partially grows again but it is thin and straggly, thus causing a noticeable cosmetic defect – difficult to conceal. In children, already severely tried by the ordeals of many years of oncological therapy, it may lead to profound psychological trauma.

In 1959 Norman Orentreich pioneered alopecia treatment with hair follicle transplantation [18]. The basic assumption of this method was that scalp from occipital area does not go bald and, when transferred to scalp areas affected by balding, retains its original properties, which result in hair re-growth. Many years of clinical experience confirmed the validity of this thesis. In the initial period grafts were 4-5 mm in diameter. Although good hair regrowth was achieved, the cosmetic effect left a lot to be desired. The hair grew in clumps and did not look natural. In order to improve the cosmetic effect Nordstrom was first to propose the use of micro-grafts of 1-3 hairs [19, 20]. Such minute grafts considerably improved the cosmetic effect, especially in the frontal area. In 1986 Carlos Uebel [20, 21] started performing massive surgery using 1000 micrografts. This technique gained popularity in the late 1990's. At present a standard procedure makes use of 1500-3000 micro- and mini-grafts. Such treatment is usually applied in the correction of androgenic alopecia in men and women [22-26]. Good mastering of this technique made it possible to use autogenic hair follicle transplantation in post-trauma and post-irradiation alopecia treatment. Our experiences with androgenic alopecia treatment began in 1984. After a few years we used it for the treatment of post-irradiational alopecia. We used this therapy to treat II, III and IV grade scalp damage according to the WHO classification [1, 10]. Visible post-irradiation lesions in the scalp, as reflected by endogenous collagen hyperplasia and poor blood flow to the skin, necessitated the introduction of certain modifications. The number of grafts placed at a single procedure had to be limited and larger spaces (up to 2-3 mm) had to be kept between grafts. In androgenic alopecia treatment this distance is 1-1.5 mm. Thus 30-40 grafts can be placed on 1 cm<sup>2</sup>.

In post-radiation alopecia treatment the density does not exceed 15-20 grafts per 1 cm<sup>2</sup>. When it is necessary to place grafts on a vast area of the head it is often performed in stages, and grafts are placed concentrically from the circumference to the central part of the bald spot. Intervals of several months are kept between stages.

It is extremely important to keep particular asepsis in radiotherapy patients. Poor blood supply to the treated scalp areas makes them more prone to infection. Additionally, antibiotic prophylactics is of utmost importance. In cases where there is worse blood supply to the recipient area Frechet recommends that a 2% Minodixil solution is used for a month before the planned procedure [27]. It is supposed to improve capillary proliferation

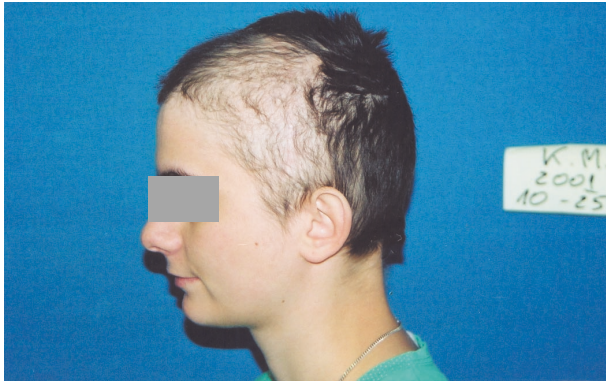


Figure 1A

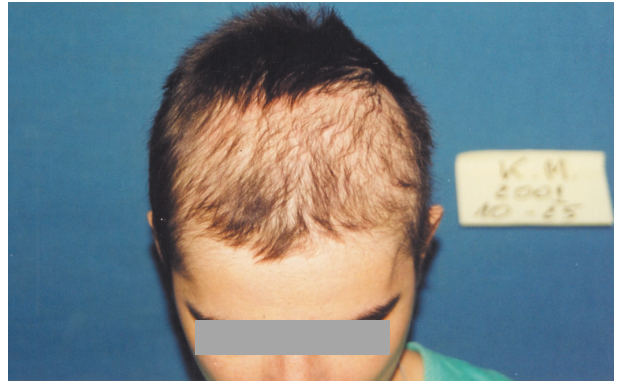

Figure 1B

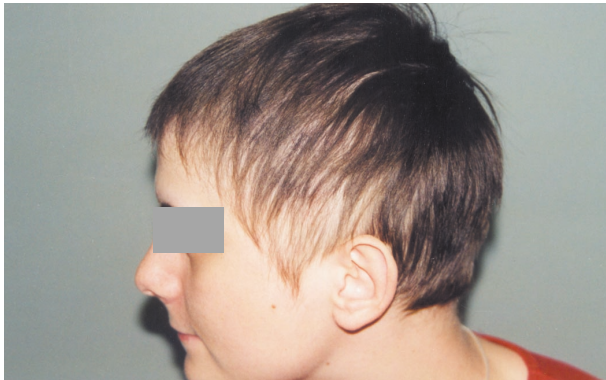

Figure 1C

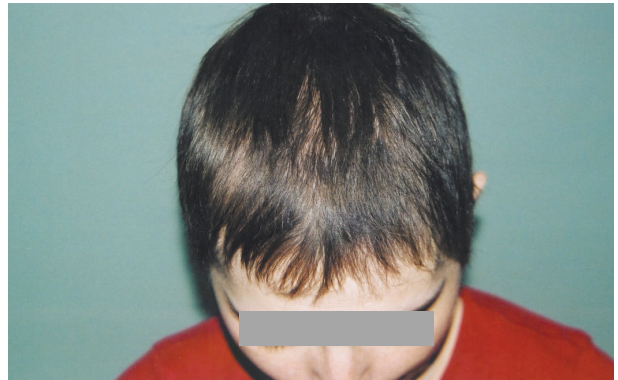

Figure 1D

Figure 1. A i B – Girl, 18 years old, after surgery and radiotherapy for *meningioma menindotheliale cum signis anaplasticis*. Visible balding in the frontal, parietal and left occipital areas.

C i D – View 6 months after surgery with 1270 micr- and mini grafts

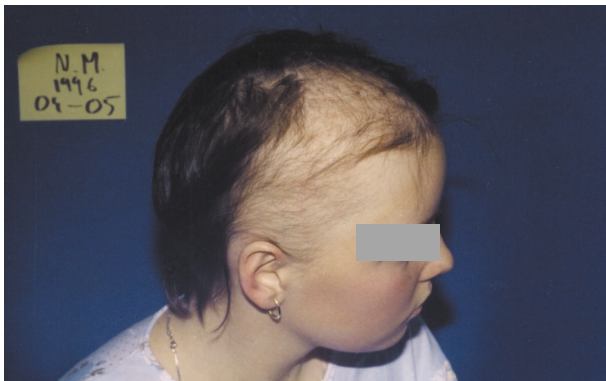

Figure 2A

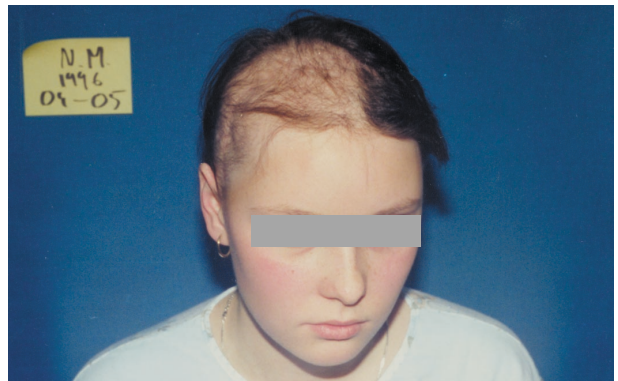

Figure 2B

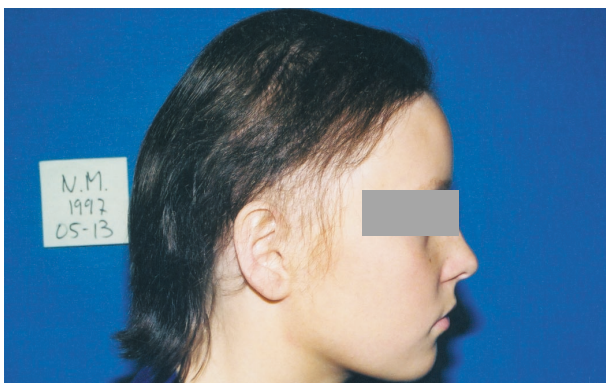

Figure 2C

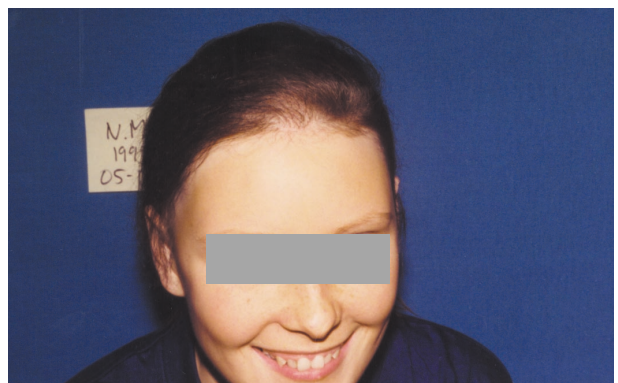

Figure 2D

Figure 2. A i B – Girl, 15 years old, after radiotherapy due to lymphatic leukemia. Visible balding in the frontal, parietal and right occipital areas.

C i D – View after hair transplantation – two surgical sessions with a total of 1890 micro- and mini grafts

in this area. Another important aspect is procedure duration. Kim demonstrated that graft vitality reduces after 4 hours from the collection [28]. The application of the technique 'four hands stick and place' maximally shortens the most time-consuming stage of the procedure, which is graft placement within the balding areas. It consists of immediate graft introduction in the incisions. It also enables a more accurate adjustment of incision size to graft size and reduces intraoperational bleeding, while at the same time it prevents the placement of two grafts in one incision.

Hair regrowth in radiotherapy patients occurs later than in patients with androgenic alopecia – being 4-5 months and 3 months, respectively. This calls for greater patience on the part of doctors as well as patients.

In cases of post-radiotherapy alopecia expander therapy is not used [29-31], as it carries a greater risk of infections. Also, as has already been mentioned, post-radiotherapy skin is characterised by poorer blood supply, which might have a detrimental effect on vitality of skin flaps used in this method.

A properly performed hair transplantation procedure in post-irradiation alopecia patients gives good and, sometimes, even very good cosmetic effects (Figures 1 and 2: A, B, C, D). Not only is appearance improved but also the patients' psyche is boosted. The procedure dramatically improves the patients' quality of life.

## Conclusions

Radiotherapy within the area of the head very often results in permanent alopecia of certain scalp areas.

A treatment of choice in post-radiotherapy alopecia is autogenic hair follicle transplantation.

A properly performed hair transplantation procedure gives very good cosmetic effects and considerably improves patients' quality of life.

**Jerzy Kolasiński MD, PhD**

ul. Staszica 20A

62-020 Swarzędz – Nowa Wieś

e-mail: info@hair-clinic.poznan.pl

## References

1. Archambeau JO, Pezner R, Wasserman T. Pathophysiology of irradiated skin and breast. *Int J Radiat Oncol Biol Phys* 1995; 31: 1171-85.
2. Anscher MS, Kong FM, Murase T et al. Short communication: Normal tissue injury after cancer therapy is a local response exacerbated by an endocrine effect of TGF beta. *Br J Radiol* 1995; 68: 331-3.
3. Bernstein EF, Salomon GD, Harisiadis L et al. Collagen gene expression and wound strength in normal and radiation impaired wounds. *J Dermatol Surg Oncol* 1993; 19: 564-70.
4. Gorodetsky R, McBride WH, Withers HR et al. Effect of fibroblast implants on wound healing of irradiated skin: Assay of wound strength and quantitative immunohistology of collagen. *Radiat Res* 1991; 125: 181-6.
5. Gorodetsky R, Mou X, Fisher DR et al. Radiation effect in mouse skin: Dose fractionation and wound healing. *Int J Radiat Oncol Biol Phys* 1990; 18: 1077-81.

6. Markowska J, Czub M and Gluszek B. Retrospective appraisal of intensity of skin postradiation reactions in breast cancer patients treated with telebrachytherapy. *Eur J Gynaecol Oncol* 1994; 15: 372-4.
7. Dische S, Warburton MF, Jones D et al. The recording of morbidity related to radiotherapy. *Radiother Oncol* 1989; 16: 103-8.
8. Nuutinen J, Lahtinen T, Turunen M et al. A dielectric method for measuring early and late reactions in irradiated human skin. *Radiother Oncol* 1998; 47: 249-54.
9. Turesson I, Nyman J, Holmberg E et al. Prognostic factors for acute and late skin reactions in radiotherapy patients. *Int J Radiat Oncol Biol Phys* 1996; 36: 1065-75.
10. Ranu HS. Effects of radiotherapy on the mechanical properties of human skin. *IEEE Engineering Med Biol* 1991; 1: 55-7.
11. Withers HR, Thames HD, Peters LJ. Differences in fractionation response of acute and late responding tissues. *Prog Radiooncol* 1982; 2: 287-96.
12. Baker MR, Bader D, Hopewell JW. The effects of single doses of x-rays on the mechanical properties of pig skin in vivo. *Br J Radiol* 1989; 62: 830-7.
13. Hopewell JW. The skin: Its structure and response to ionizing radiation. *Int J Radiat Biol* 1990; 57: 751-73.
14. Martin M, Lefaix JL, Pinton P et al. Temporal modulation of TGF- $\beta$ 1 and b-actin gene expression in pig skin and muscular fibrosis after ionizing radiation. *Radiat Res* 1993; 134: 63-70.
15. Turesson I. The progression rate of late radiation effects in normal tissue and its impact on dose-response relationships. *Radiother Oncol* 1989; 15: 217-26.
16. Turesson I. Individual variation and dose dependency in the progression rate of skin telangiectasia. *Int J Radiat Oncol Biol Phys* 1990; 19: 1569-74.
17. Warszawski A, Rottinger EM, Vogel R et al. 20 MHz ultrasonic imaging for quantitative assessment and documentation of early and late postradiation skin reactions in breast cancer patients. *Radiother Oncol* 1998; 47: 241-7.
18. Orentreich N. Autografts in alopecia and other selected dermatological conditions. *Ann NY Acad Sci* 1959; 83: 463-9.
19. Nordström REA. "Micrografts" for improvement of the frontal hairline after hair transplantation. *Aesthet Plast Surg* 1981; 5: 97-101.
20. Uebel CO. A new method for pattern baldness surgery. Free paper presented at Jornada Carioca Cirurgia Plastica, Rio de Janeiro, Brazil, August 1986.
21. Uebel CO. Micro and minigrafts. A new approach to baldness surgery. *Ann Plast Surg* 1991; 27: 476-81.
22. Stough DB. III Punch scalp autografts for bald spots. *Plast Reconstr Surg* 1968; 42: 450-57.
23. Vallis CP. Hair transplantation for male pattern baldness. *Surg Clin North Am* 1971; 51: 519-23.
24. Barrera A. Micrograft and minigraft megasession, hair transplantation. Review of 100 consecutive cases. *Aesthet Surg J* 1997; 17: 165-72.
25. Rassman WR, Carson S. Micrografting in extensive quantities. The ideal hair restoration procedure. *Dermatol Surg* 1995; 21: 306-11.
26. Stough DB. Single hair grafting for advanced male pattern alopecia. *Dermatol* 1993; 6: 11-17.
27. Frechet P. Scalp extension. *J Dermatol Surg Oncol* 1993; 19: 616-23.
28. Stough DB. Hair transplantation by the feathering zone technique: new tools for the nineties. *Am J Cosm Surg* 1992; 9: 243-8.
29. Manders EK, Au VK, Wong RKM. Scalp expansion for male pattern baldness. *Clin Plast Surg* 1987; 14: 469-73.
30. Adson MD, Anderson RD, Argenta LC. Scalp expansion in the treatment of male pattern baldness. *Plast Reconstr Surg* 1987; 79: 906-12.
31. Kolasiński J, Zieliński W, Kolenda M. Leczenie rekonstrukcyjne pooperacyjnych ubytków skóry owłosionej głowy. *Roczniki Oparzeń* 1996-97; 7/8: 207-18.

Paper received: 21 August 2002

Accepted: 7 October 2002